

A Rare Case of Denture Fittings Leading to *Streptococcus Salivarius* Meningitis

Shawn Ferris, OMS-III¹, Nathan Yobst, OMS-III¹, Yen Quach, MD²

¹DeBusk College of Osteopathic Medicine, Lincoln Memorial University, Knoxville, TN 37932

Methodist Family Medical Center, Covenant Medical Group, Oak Ridge, TN 37830



Introduction

- We report a rare case of *Streptococcus salivarius* following a recent dental-fitting procedure.
- Meningitis is a life-threatening inflammation of meninges surrounding brain and spinal cord. Etiologies include bacterial, viral, and fungal infections.
- Empiric treatment includes Ceftriaxone, Vancomycin, Ampicillin, and Acyclovir if viral meningitis is considered.
- Lumbar puncture with CSF analysis is the gold standard for diagnosis.
- Because bacterial meningitis can rapidly progress, empiric treatment should be started immediately when clinical suspicion is high.
- This case highlights:
 - The importance of obtaining cultures before antibiotic administration.
 - The diagnostic challenges created by empiric treatment
 - The value of patient history in identifying atypical pathogens
 - Potential association between dental procedures and invasive *S. Salivarius* infection.

	Appearance	Opening Pressure mmHg	WBC (cells/mm ³)	Protein (mg/dL)	Glucose (mg/dL)
Normal	Clear	90-180	< 8	15-45	50-80
Bacterial Meningitis	Turbid	Elevated	>1000-2000	>200	<40
Viral Meningitis	Clear	Normal	<300; Lymphocytic predominance	<200	Normal
Fungal Meningitis	Clear	Normal-elevated	<500	>200	Normal - Low

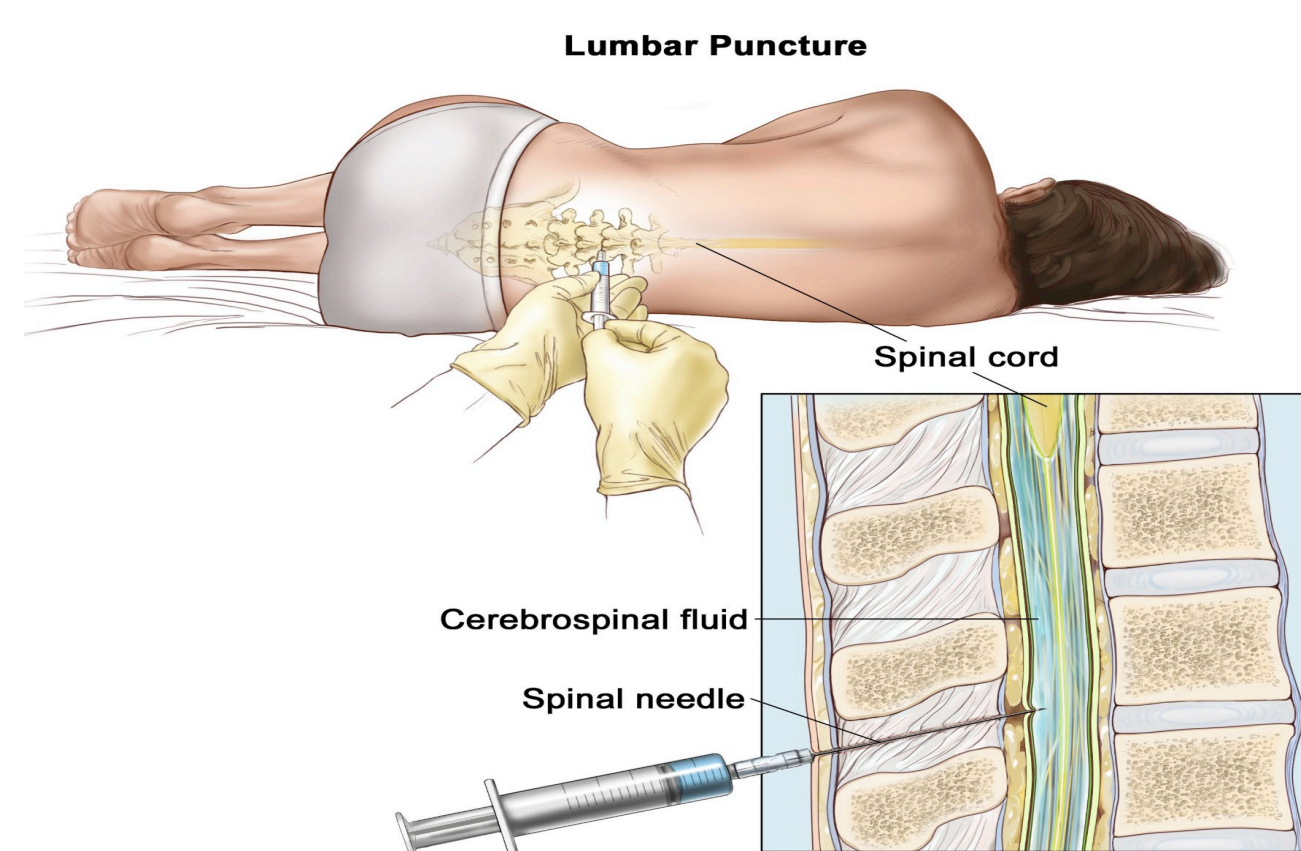


Image 1: CSF Analysis

Image 2: Lumbar Puncture

Case Presentation

Patient History:

- A 72-year-old female patient with a history of hypertension, hypothyroidism, and psoriatic arthritis who presented to the hospital due to 1 day history of headache, photophobia, nausea, and vomiting that had progressively gotten worse.
- Patient reported she had taken acetaminophen for pain control. The patient was being treated for psoriasis treated with deucravacitinib.
- On admission, the patient began experiencing neck stiffness and altered mental status. She was febrile, tachycardic, tachypneic, and hypertensive. Patient reported having a recent denture procedure.

Management and Outcome:

- Labs showed leukocytosis and elevated inflammatory markers. Blood cultures grew *Streptococcus salivarius*.
- Patient treated empirically for suspected meningitis on with Vancomycin, Rocephin, Acyclovir, and Ampicillin.
- Patient admitted to the hospital and managed for bacteremia, sepsis, and bacterial meningitis.
- LP was ordered, and CSF analysis showed elevated WBC, elevated protein, and low levels of glucose. CSF culture was negative for growth.
- The patient's antibiotics were narrowed to IV Ceftriaxone based on the blood culture.

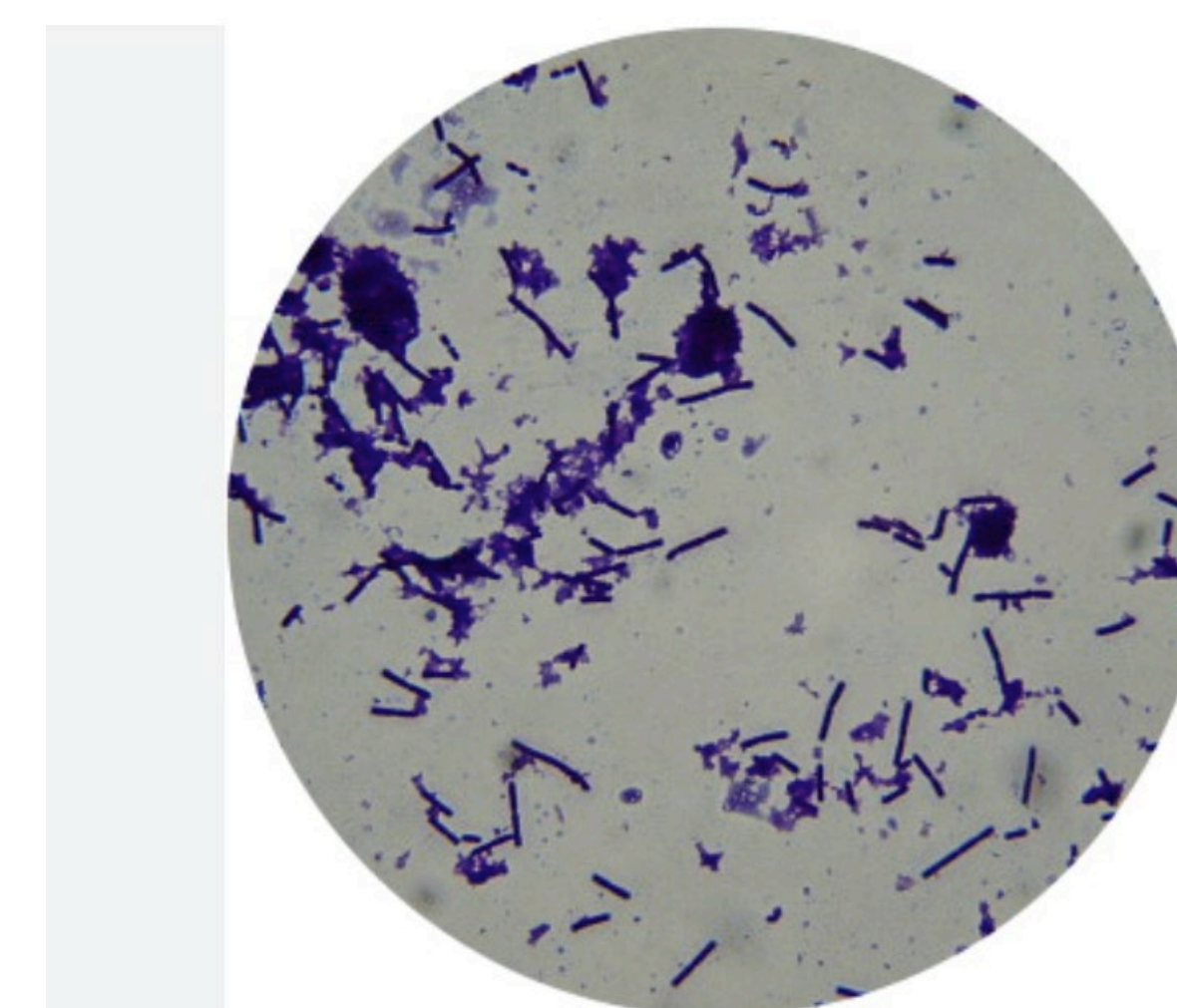


Image 3

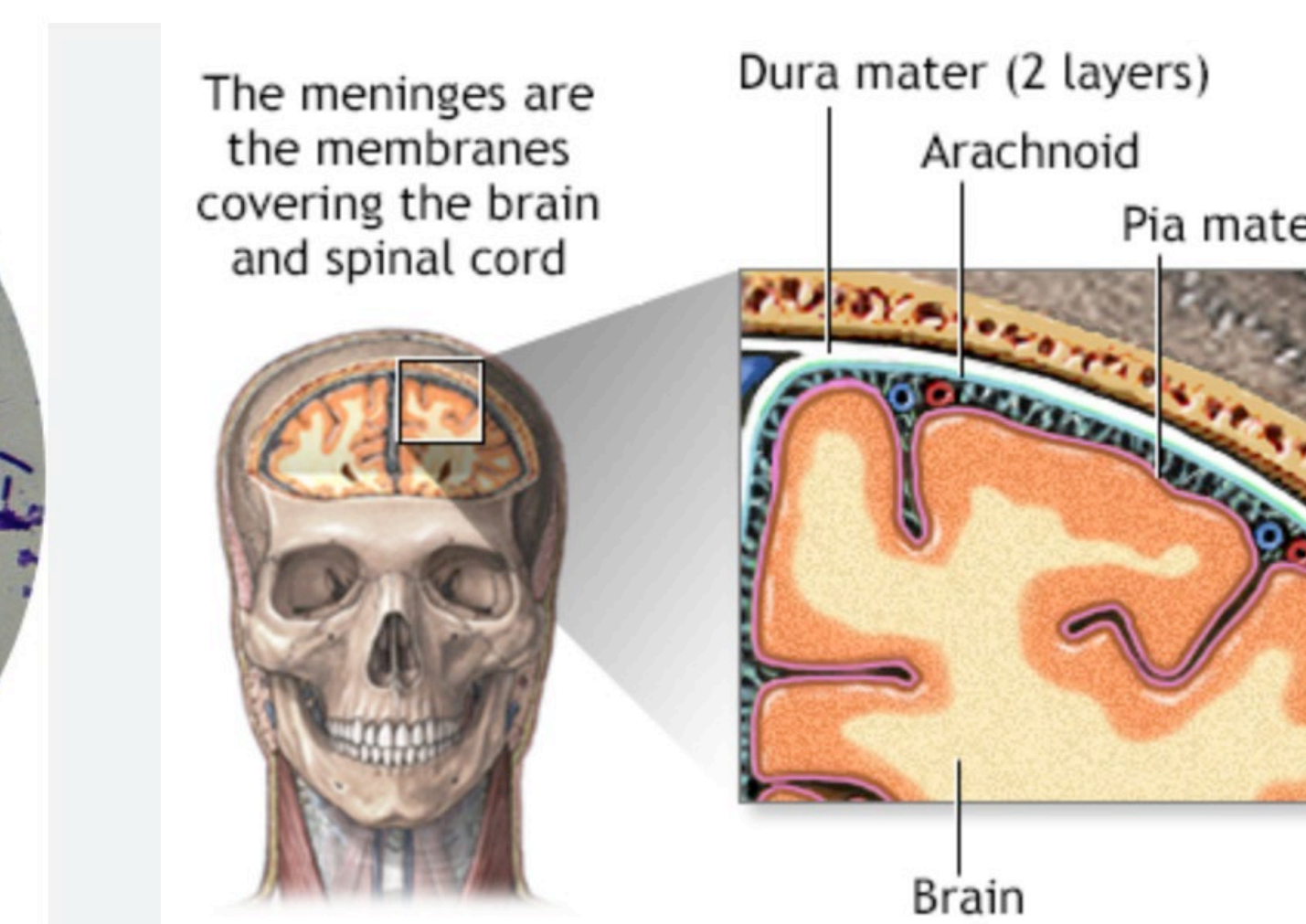


Image 4

Discussion

Discussion:

- Meningitis is a medical emergency that requires immediate initiation of broad empiric therapy. There is a significant mortality benefit when treatment is started promptly, even before definitive culture results are available (Eisen et al., 2022).
- Early empiric treatment can lead to negative CSF cultures despite an active bacterial infection. In this case, the lack of growth on CSF culture was most likely due to early empiric therapy, affecting how antimicrobial therapy is later narrowed
- The patient's clinical presentation of photophobia, headache, neck stiffness, and altered mental status were sufficient to make a clinical diagnosis of meningitis. CSF markers and blood culture growth of *S. salivarius* were used to make a diagnosis and narrow treatment.
- The patient presented in this case had reported a recent denture resulting in a portal of entry for a typically benign bacteria to enter the bloodstream. The patient's medical history was notable for psoriasis treated with deucravacitinib, a selective tyrosine kinase 2 (TYK2) inhibitor. Patient's immunosuppressive therapy with deucravacitinib may have impaired clearance of transient bacteremia, allowing sustained bloodstream infection and subsequent penetration of the blood-brain barrier, resulting in bacterial meningitis.

Conclusion

This case highlights the importance of thorough history taking, early empiric treatment, and careful interpretation of laboratory data in patients with suspected meningitis, particularly in the setting of immunomodulatory therapy. Prompt recognition and appropriate antimicrobial management allowed for treatment narrowing and contributed to a favorable clinical outcome.

References



Acknowledgements

The authors would like to thank the faculty at LMU-DCOM and Dr. Quach for support and guidance in the completion of this project.